Richard M. Conran, MD, PhD, JD
E-mail: rconran@usuhs.mil
B-3082, 295-3454 (7/03)

LABORATORY DIAGNOSIS AND CLINICAL FEATURES OF NEOPLASIA

I. CLINICAL MANIFESTATIONS OF NEOPLASIA

> Frank, a 60-year-old emaciated white male, presents to your office with chief complaint of fatigue, weight loss and a change in bowel habits. Physical exam reveals a cachectic male in no acute distress. Increased skin pigmentation in the axilla and groin is noted. Rectal exam is remarkable for occult blood in stool.
>
> What is your differential diagnosis?
>
> What signs and symptoms suggest cancer?

A. **Occult cancer**: 30 % of men over 60 years of age who die of causes other than prostatic cancer have prostatic cancer at autopsy (the number approaches 90% after 80 years of age)

B. **Symptoms**

1. _____ on tumor type and location.

C. **Signs**

1. **Local signs**

   Due to the presence of a mass: asymmetry, fixation, firmness of tissue, compression, inflammation, etc.

2. **Systemic signs**

   Low grade recurrent_____ - due to tumor antigen stimulation, necrosis of tissue or local infections

   Pruritus - mast cell hyperactivity in response to tumor, obstruction of biliary tree

   Fatigue, loss of appetite, nausea, weight loss - chronic anemia, effect of TNF

   _____ - due to (1) substances released by the tumor that have a toxic effect on the bone marrow, or (2) physical replacement of bone marrow by cancer cells (myelophthisic anemia), or (3) hemolysis of red cells due to production of autoimmune antibodies (in lymphomas).

   Jaundice - due to bile duct obstruction (cancer of the head of the pancreas)

   _____- it is the constellation of progressive weakness, malaise, loss of appetite, and emaciation in the terminal stages of cancer. There is often a direct correlation between "tumor burden" and the degree of cachexia; however, even a small primary tumor can cause this disorder. Cachexia is related to the release of peptides, TNF (= cachectin), and other chemicals by viable or dying cancer cells. Uremia in late renal failure may also contribute to cachexia. Cachexia is not caused by the excess nutritional demands of the tumor.

D. **Complications**

1. **Local complications** (caused by the growth of the tumor mass)

   _____: obstruction of the ureters can lead to hydronephrosis

   infection: obstruction of an airway can lead to post-obstructive pneumonia

   destruction of critical structures: loss of cerebral cortex with aggressive brain tumors (glioblastoma multiforme)

_____: colonic polyps and cancers can lead to hematochezia, hematuria (blood in urine) may be caused by renal cell carcinomas.

ulceration: ulceration of the esophagus leading to hematemesis (vomiting of blood)

infarction: when a tumor outgrows its blood supply, the tumor undergoes ischemic infarction

2. **Systemic complications**

Respiratory failure: Secondary to destruction of pulmonary parenchyma by metastases

Liver failure: Secondary to destruction of liver parenchyma by metastases

Pathologic fractures: Secondary to metastases to bone

Cerebral dysfunction: Secondary to metastases to brain

Chronic renal disease/failure: can be caused by

(1) immune complex deposition in glomeruli (lymphomas)
(2) renal tubular damage (light chain disease in multiple myeloma)
(3) uric acid stones
(4) calcium stones
(5) compression of ureters
(6) metastases (metastases to the kidneys is a very rare event)

Immunodeficiency (leads to opportunistic infections): due to direct tumor replacement of lymph nodes, bone marrow or other sites of immune cell production - due to the suppression of immune cell function (in lymphomas) - due to chemotherapy and radiotherapy (iatrogenic)

3. **Paraneoplastic syndrome**

A _____ is the combination of signs and symptoms in a patient with cancer that cannot be attributed to either (1) the location of the primary tumor or its metastases or (2) to the secretion of hormones indigenous to the tissue from which the tumor is derived. See Table 8-11 Robbins p.321

1. _____ **syndrome** - metabolic abnormalities secondary to excess corticosteroids. Example: production of adrenocorticotropin (ACTH) or ACTH like substances by a small cell (oat cell) carcinoma of the lung
2. **Hypercalcemia** -- there are two major mechanisms whereby tumors produce hypercalcemia (l) cancer induced osteolysis by metastatic deposits of tumor in bone (not a paraneoplastic syndrome) and (2) the production of parathyroid hormone (PTH) or PTH-like substances. Example: production of a PTH-like substance by a squamous cell carcinoma of the lung (this is a paraneoplastic syndrome)
3. **Migratory venous thrombosis** (Trousseau's thrombophlebitis) -- secondary to a poorly understood "hypercoagulable state" Example: classically described in pancreatic adenocarcinoma
4. **Disseminated Intravascular Coagulation** (DIC) -- Characterized by simultaneous thrombogenesis and thrombolysis. This disorder can be found in almost any type of advanced cancer
5. _____ **Syndrome** -- present in patients with liver metastases of tumors originating in neuroendocrine cells of the GI tract (carcinoid tumors). These tumors secrete serotonin and histamine, leading to hyperperistalsis with cramps, diarrhea, bronchospasm, and cardiac valve fibrosis (pulmonary and tricuspid valve fibrosis).
6. **Hypoglycemia** -- Example: in some sarcomas, due to the production of insulin like substances. An insulinoma secreting insulin leads to hypoglycemia, but is not a paraneoplastic syndrome

7. **Polycythemia** -- Example: in renal cell carcinomas, due to the production of erythropoietin
8. **Acanthosis nigricans** -- thickening and darkening of the skin of the axilla and groin areas seen in many types of carcinomas. The cause is unknown
9. **Non-bacterial thrombotic endocarditis** (NBTE) or marantic endocarditis -- lesions of the cardiac valves associated with cachexia seen in many cancers
10. **SIADH**

II. GENERAL APPROACH TO CANCER DIAGNOSIS

> Based on history and physical findings, colon cancer is considered in the differential diagnosis based on cachexia, change in bowel habits, and occult blood in stool. The increased pigmentation is consistent with acanthosis nigricans.
>
> How do we confirm the diagnosis?

Diagnosis is a team effort: it starts with the patient's primary physician (history, physical exam, lab data) and involves numerous specialists- radiologist (X-rays, CT scan, MRI), surgeon (biopsy, excision), pathologist (diagnosis) and oncologist (treatment).

Diagnosis is made by pathologic examination of tissue obtained from a biopsy or surgical resection

Tissue samples must be obtained from the correct location.

Interpret the histopathology or cytopathology in the context of fiberoptic, radiographic, and laboratory data.

III. PATHOLOGIC CLASSIFICATION AND NOMENCLATURE

> Based on radiologic studies showing a mass in the large intestine, Frank is referred to a surgeon who schedules a hemicolectomy. During the procedure, a large lymph node is removed and sent to pathology for a frozen section diagnosis. A diagnosis of “adenocarcinoma present” is returned to the surgeon.
>
> What does this term mean?

All tumors have two basic components: (I) proliferating neoplastic cells that constitute their *parenchyma* and (2) *supportive stroma* composed of connective tissue, blood vessels and lymphatics. The parenchymal cells determine the nature of the neoplasm and hence the nomenclature of tumors is usually based on the parenchymal component. Tumors are classified as benign or malignant and whether they are of epithelial or mesenchymal origin.

_____ = a benign tumor arising from glandular or secretory epithelium
PAPILLOMA = a benign tumor arising from non-secretory epithelium
_____ = a malignant neoplasm of epithelial stem cell origin
SARCOMA = a malignant neoplasm of mesenchymal stem cell origin

EPITHELIAL TUMORS	BENIGN	MALIGNANT
Stratified Squamous	Squamous Cell Papilloma	Squamous Cell Carcinoma
Glandular	Adenoma	Adenocarcinoma
	Papilloma	Papillary Carcinoma
	Cystadenoma	Cystadenocarcinoma
Liver Cells	Hepatic Adenoma	Hepatocellular Carcinoma (Hepatoma)
Neuroectoderm	Nevus	Melanoma
Transitional	Transitional Cell Papilloma	Transitional Cell Carcinoma
Germ Cells		Seminoma, Embryonal Carcinoma

Mesenchymal Tumors	Benign	Malignant
Connective Tissue	Fibroma	Fibrosarcoma
	Lipoma	Liposarcoma
	Chondroma	Chondrosarcoma
	Osteoma	Osteosarcoma
Endothelium	Hemangioma	Angiosarcoma
	Lymphangioma	Lymphangiosarcoma
Blood Cells		Leukemia
		Lymphoma
Muscle Smooth	Leiomyoma	Leiomyosarcoma
Skeletal	Rhabdomyoma	Rhabdomyosarcoma

For more detail see Table 8-1, *Robbins*, p. 263

Oncologists often refer to *solid tumors* which means a tumor that does not derive from blood cells: leukemias and lymphomas are not considered solid tumors because the cells do not form cohesive masses with a vascular stroma. Nomenclature terminology is confusing. Note: the suffix "oma" does not always denote a benign neoplasm. Lymphoma, hepatoma, seminoma and melanoma are all malignant.

Teratoma- neoplasm containing cells derived from more than one germ layer. They contain fragments of bone, cartilage, epithelium, fat, nerve and muscle. Teratomas may be benign (mature teratoma) or malignant (immature teratoma).

Hamartoma- mass of disorganized tissue indigenous to a specific site.

Choristoma (heterotopic rest)- developmental lesion where non-neoplastic tissue is located at an abnormal site.

IV. **IMPORTANCE OF EARLY DIAGNOSIS**

During Frank's evaluation, his wife mentions that he had been seen by a physician 5 years ago and some polyps were removed from his intestine.

Are there lesions that are precancerous and require close follow-up?

A. Cancer often progresses from a precursor (premalignant, preinvasive, in-situ) lesion.

WBSaunders Robbins Fig 18-52

_____ - disorderly growth of epithelium where there is variation in cell size and shape (pleomorphism) and loss of architectural orientation. When the dysplastic cells involve the entire epithelial surface, the lesion is called **carcinoma in situ**. The risk of progression to invasive cancer depends on the grade and duration of dysplasia and location. Early diagnosis is imperative. Cytologic screening (Pap smear) is helpful and surgical excision is curative.

Precancerous Lesion	Neoplasm
Chronic Atrophic Gastritis	Gastric Carcinoma
Atypical Duct Hyperplasia	Infiltrating Duct Carcinoma
Atypical Endometrial Hyperplasia	Endometrial Carcinoma
CIN	Squamous Carcinoma
PIN	Prostatic Adenocarcinoma
Actinic Keratosis	Squamous Carcinoma
Glandular Metaplasia (Esophagus)	Adenocarcinoma
Ulcerative Colitis	Adenocarcinoma
Villous Adenoma	Adenocarcinoma

B. Certain tumors have been shown to be transmitted in a mendelian fashion. They include retinoblastoma, familial polyposis coli, and multiple endocrine neoplasia. A number of inherited conditions (phakomatoses, DNA-chromosomal instability and immune deficiency syndromes) are at risk for developing cancer. For more information and additional examples see Table 8-6, p. 275, *Robbins*. Screening in these patients is imperative.

The specimen removed at surgery is sent to pathology for diagnosis.

What features are used to diagnose cancer?

V. GROSS FEATURES OF NEOPLASIA

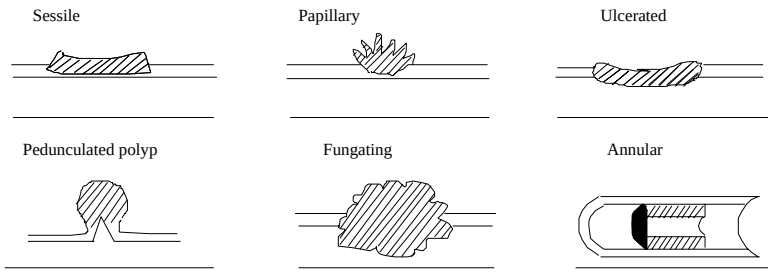

Figure 9-1(modified from Underwood JCE, *General and Systematic Pathology*, p227)

Grossly, tumors can be classified as sessile, pedunculated, papillary, fungating, ulcerated, or annular. The latter three are almost always malignant.

In some tumors the stromal support is scant, and so the neoplasm is soft and fleshy, but sometimes the parenchymal cells stimulate the formation of an abundant collagenous stroma - referred to as ***desmoplasia***. Such tumors may become stony hard or ***scirrhous***. Fibrosis and dystrophic calcification may give tumors a gritty character when cut across.

VI. GENERAL CRITERIA IN HISTOPATHOLOGIC CANCER DIAGNOSIS

A. **nuclear morphology** -- nuclear changes including, _____ (variation in size and shape of the nuclei), increased _____ ratio (N::C ratio), _____ (increased nuclear chromatin), atypical mitotic figures (tripolar, quadripolar, or multipolar mitotic spindles) and nuclear position (loss of polarity in mucosal epithelium) are features of malignancy.

B. **cellular pleomorphism** -- variation in shape and size of cells, cells have an increased nuclear cytoplasmic ratio (nuclear cytoplasmic ratio of 1:1 versus a normal ratio of 1:4 to 1:6), tumor giant cells may be present

C. **mitoses** -- increased mitotic rate indicates abnormal sustained growth. Abnormal mitotic figures may indicate aneuploidy

D. **differentiation** -- the extent to which parenchymal cells resemble normal cells and tissues. Loss of normal cell products (keratin or mucin) or loss of tissue cohesion are signs of poor differentiation. Anaplasia- neoplastic cells have no resemblance to normal tissue

E. _____ - evidence of breaching basement membrane or breaching a "capsule" with "infiltrative" growth pattern into contiguous tissues, blood vessels or lymphatics.

F. _____ - evidence of local or systemic dissemination of neoplasm via the lymphatic or blood circulation

> Post-operatively, you relay the diagnosis to Frank. His question is “How long do I have to live?”
>
> What pathologic features can be used to discuss prognosis?

VIII. **GRADING**

This is an effort to quantify the histopathologic/ cytopathologic deviation of a tumor from normal tissue.

Grading requires microscopic examination of tissue sections. This is different from staging.

Staging is based on the size of the primary tumor and its spread to lymph nodes and different organs. It is not based on the degree of differentiation of the tumor cells.

IMPORTANT!!!
Do not confuse staging with grading of a malignant neoplasm. **Grading refers to differentiation**. If a malignant neoplasm appears histologically similar to normal tissue, we say that a tumor is a well differentiated. If there is only a hint of similarity with normal tissue, we say that it is a poorly differentiated. Somewhere in between, a tumor is a moderately differentiated. A tumor that does not resemble the normal tissue at all is designated undifferentiated or **anaplastic**.

Grading terminology includes:

"well differentiated" = "_____" = grade I or II
"moderately differentiated" = "intermediate grade" = grade II or III
"poorly differentiated" = "high grade" = grade III or IV
"anaplastic" = "undifferentiated" = "_____" = grade IV

Grading is of prognostic importance for some neoplasms insofar as it correlates with how aggressively an untreated cancer will behave and how it may respond to therapy. The best clinical correlations are with some carcinomas for example, thyroid cancer, transitional cell carcinoma of the bladder and prostate adenocarcinoma. It is critical to recognize that the significance of specific histopathologic or cytopathologic findings varies from one type of neoplasm to another. Experience correlating histopathology with the natural history (biologic and clinical behavior) of cancers and therapeutic modalities has developed over many decades and continues to grow. Predictions of how a tumor will behave are based on cumulative past experience after seeing numerous neoplasms with a similar morphology and pattern of growth.

IX. **STAGING OF NEOPLASMS**

Staging is based on:

(l) the size of the primary lesion
(2) the extent of spread to regional lymph nodes (local metastasis)
(3) the extent of systemic spread (distant metastases)
(4) staging sometimes includes a clinical feature (pruritus or fever in Hodgkin's disease)

Staging is of fundamental importance in **establishing the prognosis** of a cancer.
At first, staging may be based on clinical parameters ("clinical staging")
Definite staging is done only after biopsies and/or open surgery and exploration with histopathologic or cytologic diagnosis of appropriate specimens.

Examples:
a. TNM system (World Health Organization = WHO)

T = size of the primary tumor (Tl, T2, T3)(T0 is in situ
N = number and location of lymph node involvement (N0, Nl, N2...)
M = extent and location of metastasis (M0, Ml, M2...)

b. Adenocarcinoma of the colon (Dukes)

Stages A to D based on the extent of wall invasion (from invasion into mucosa to distant metastases) INSERT FIG 13-60 RUBIN

What other features are helpful in diagnosis, prognosis and management of cancer?

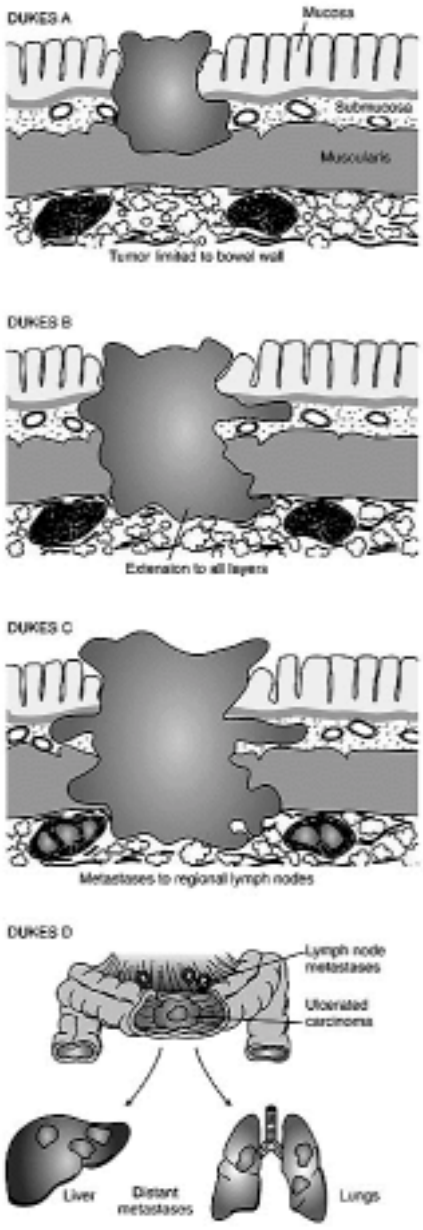

Fig. 13-60, from Pathology, 3rd ed. by Rubin and Farber Reproduced with permission

X. **SPECIFIC TUMOR MARKERS** (For more details and examples see Table 8-12, p. 325, *Robbins*.)

A. **Hormone products** (endogenous or ectopic)
e.g. human chorionic gonadotropin (β-hCG) in trophoblastic tumors and testicular cancer

B. **Oncofetal antigens**
1. carcinoembryonic antigen (CEA) -- e.g. many cancers of endodermal origin: colonic, pancreatic, gastric
2. alpha-fetoprotein -- hepatoma, testicular cancer

C. **Mucins**
CA-125 Ovarian cancer

D. **Proteins**
1. prostate specific antigen (PSA) - prostatic cancer
2. immunoglobulins-multiple myeloma

XI. **DNA CONTENT**
Many malignant tumors have abnormal DNA content and are termed DNA aneuploid. Other tumors have normal or normal-range DNA content and classified DNA diploid. DNA content can be measured by flow cytometry and is an useful indicator of the aggressiveness for some tumors.

XII. **CELL CYCLE ANALYSIS**
The DNA content of cells varies during the resting and growth phases of each cell's cycle and can be conveniently measured by flow cytometry. For most tissue cell populations, the bulk of cells are in G0/Gl (60-98%) with the remainder divided between S-phase (1-30%) and G2/M (1-10%). In solid tumors the percentage of cells in S-phase correlates with the thymidine labeling index and may reflect the rate of tumor growth.

XII. **KARYOTYPIC CHANGES**

In many types of human cancers consistent and specific chromosomal abnormalities have been identified. Most of these chromosomal alterations have become evident with high-resolution chromosome banding techniques. Some important examples: deletion of short arm of chromosome 1 in neuroblastoma, reciprocal translocations between chromosomes #8 and #14 in Burkitt's lymphoma, and a reciprocal translocation between chromosomes #9 and #22 (Ph^1= Philadelphia chromosome) in chronic myelogenous leukemia (CML) (see Figure 8-8, p 286).
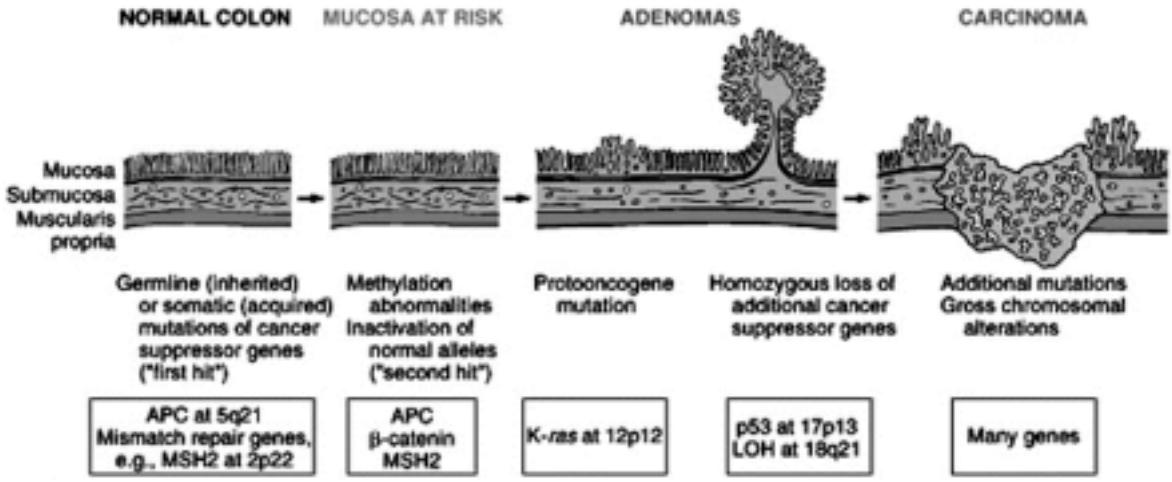
XIII. **MOLECULAR EVIDENCE OF GENE REARRANGEMENTS**